

clinical and neurological disorders in children against the background of a previous herpesvirus infection

Shuhrat Niyazov¹, Aziza Djurabekova², Gulandon Khakimova³

Samarkand State Medical Institute, Republic of Uzbekistan, Samarkand.

Abstract - Despite a significant amount of research on herpesvirus lesions of the nervous system in children, questions regarding the diagnosis of the spectrum of forms of the disease, the fight against the consequences of the disease, many points remain open. The paper presents cases of damage to the central and peripheral nervous system by the herpes simplex virus in children, features of the course, clinical and neurological forms, the prognosis of the disease depending on the severity.

Keywords: children, herpes simpleks virus, damage to the nervous system.

INTRODUCTION

Diseases caused by viruses are the most common and have a wide range of clinical manifestations. Using various mechanisms, they cause damage to the nervous system, leading to encephalitis, meningoencephalitis, meningoencephalomyelitis, and in some cases lead to demyelination [2, 3]. According to data for 2020 WHO studies, ranked second in mortality [6, 7]. And as information sources show, diseases caused by viruses do not lose their relevance, and are not only of medical but also social significance. The share of the total number of cases of all viruses, depending on the frequency of CNS damage, more than 25% falls on the herpes simplex virus [1, 2]. The source of herpesvirus infection is persons infected (carriers) with the virus. The virus in its manifest form is found in blood and urine, less manifested in biological fluids (mucus from the nasopharynx, amniotic fluid, lacrimal fluid, etc.) [5, 6]. The main route of transmission is sexual, transplacental, airborne, alimentary (contact), through the skin. The penetration of the virus into the nervous system has not yet been established, assumptions based on experimental studies make one think about spreading through the olfactory tract, ethmoid bone. PCR and ELISA studies have become the gold standard

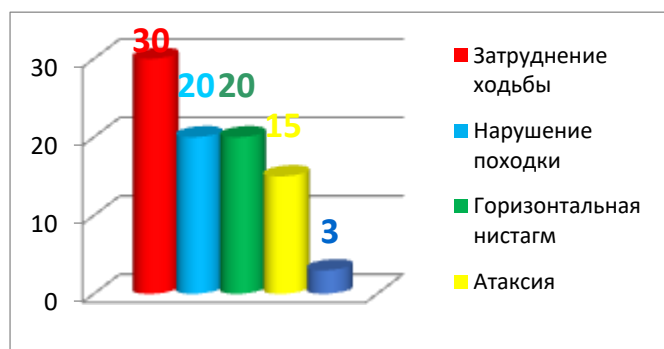of diagnostics, but for a complete picture in the diagnosis it is necessary to include neuroimaging and neurophysiological studies of the approach to the problem.

Aim. To study the features of clinical forms of lesions of the nervous system by the herpes simplex virus in children, using an integrated approach to diagnosis.

MATERIAL AND RESEARCH METHODS.


The work was carried out in several stages, the collection of material took place in several clinical bases: an infectious diseases hospital, private clinics ("Innova", "Med Expert"), the 1st clinic of SamMI, the department of intensive care and pediatric neurology, the base of the children's multidisciplinary hospital in Samarkand. During the acute stage of the disease, patients were examined by an infectious disease specialist, neurologist, pediatrician. Children admitted to the hospital underwent laboratory tests proving the involvement of herpes simplex (HS) in the disease. The total complexity was 60 patients, ranging in age from 1 to 10 years. Male gender predominated 39 patients, female 21 patients. The second stage was undergoing rehabilitation treatment for these patients in specialized departments, including MRI and EEG diagnostics. Of the patients examined in the early period of the disease, 50 participated in the examination of the second stage (parental refusal). Of these, 25 are males, and 25 are females (the numbers were specially identical for better analysis). All patients underwent a clinical and neurological examination, including complaints, epidemiological premorbid analysis. Standard blood and urine tests; The division of children into groups was in accordance with the clinical and neurological symptoms and in accordance with the diagnosis. Group I children with meningoencephalitis and encephalitis (17), group II diagnosed with cerebellar ataxia (20), group III children with lesions of the peripheral nervous

system polyneuropathy (13), this group (III) children additionally studied electroneuromyography (ENMG). Statistical processing was carried out on an individual computer with the calculation of the maximum and minimum values, the reliability equation.



Parents did not immediately notice signs of instability, the first symptoms were lack of appetite (nausea). Of the 20 children of group II, 15 of them underwent an MRI scan (in some cases, urgently, to exclude hemorrhage, as a complication of herpesvirus infection). During the neurological examination, attention is drawn to the absence of meningeal symptoms. In older children (after 3 years), instability was noted in the Romberg position. When checking the finger test, waving and intentional tremor were noted in two patients; Difficulty repeating the movement (adidahokinesis) is offered to children in the form of a game. From the side of the motor sphere, hypotonia was not expressed, with the preservation of reflexes. While testing the jump reaction in older children, there was a threat of falling. The group of children with meningoencephalitis and encephalitis against the background of a previous herpesvirus infection is practically, in number, similar to the group of cerebellar ataxia. But in terms of severity and prognosis, this group was marked by an unfavorable composition. The diagnosis was made on the basis of ICD10, and taking into account focal neurological symptoms, and additional research methods. Meningeal signs in combination with lesions of the brain substance (meningoencephalitis) occur in more than half of cases, 52%. The disease in children of this group began with fever, vomiting, convulsions, and involvement (lesion) of the left half of the body in 6 children, the right half of the body of 9 children, with a combination of both sides

in three children. On the second day, the level of consciousness, and in four cases reaching coma, there was a profound disturbance, as noted above, in 10 children, rigidity of the occipital muscles (meningeal signs) was found.



Paresis were central in nature, with increased tone, reflexes, with signs of pathological reflexes on the affected side. Convulsions were more common once, in one case they were repeated throughout the entire acute period (tonic-clonic). On the 7-10th day the consciousness cleared up, the condition stabilized, the clinical and neurological examination revealed left-sided, right-sided, or tetraparetic paresis. The computer images reflected the displacement of the central structures of the brain, areas of necrosis of brain cells in the temporal and frontal regions. Edema zones are visible in the affected areas. On the 20th day in two children, the signs of paresis (left-sided) are poorly expressed, that is, there was a recovery of focal symptoms, which, according to literature data, confirms the peculiarity of herpesvirus infection.

The third group of children turned out to be in smaller numbers and had a better prognosis than the group with encephalitis. The clinical picture consisted of movement and sensory disorders. The difficulty of diagnosis was that children (especially early age) cannot clearly define objective and subjective feelings. And at the same time, drawing on the experience of specialists, pain was the main source of concern for children. The pain was in the nature of a burning sensation, localized in the distal regions. Movement disorders, like sensory ones, began in 100% of cases, were peripheral, flaccid paresis, decreased or absent reflexes in the distal regions. Weakness of muscle strength in hands and feet, cold to the touch. According

to the results of the electroneuromyograph, a pronounced manifestation of polyneuropathy of an axonal-demyelinating nature with damage to the motor and sensory fibers of both the lower and upper extremities was noted. Of course, this study was conducted in older children. Recovery in all children came in different ways, but in most cases (patients with mild and moderate forms, without respiratory disorders were considered), pain sensations decreased on days 10-14, in 10 children they completely disappeared, movements in the hands and feet returned to normal. On days 16-18, the children walked and ate on their own. On ENMG positive dynamics in the form of improved excitability.

Thus, herpesvirus infection can cause severe damage to the nervous system in children, with various clinical forms such as meningoencephalitis and encephalitis, cerebellar ataxia and polyneuropathy. No correlation data were found between age, sex and clinical forms of lesions of the nervous system. In all forms, there is an acute onset, with cerebral disorders in the form of fever, vomiting, changes in consciousness, with subsequent manifestations of neurological symptoms and a relatively favorable prognosis.

References:

1. Abdumajid Mavlonboyevich Ikromov, Aziza Takhirivna Djurabekova, Farrukh Farkhodovich Samatov. Bioelectrical activity in children with malformation of the brain // Journal of Neurology and Neurosurgical Research. -2020/10/23
2. Shukhrat Toshtemirovich Niyozov, Aziza Takhirivna Djurabekova, Dilnoza Salimovna Shomurodova. Bolalardagi ikkilamchi encephalitlarning ohibatlarini bakholash / Biomedicine va amaliyot journals // 2020/10/19; 5 <https://biomedicine.tadqiqot.uz/index.php/biomedicine/article/download/57/56>.
3. S. Igamova, D. Shomurodova, A. Djurabekova. Features of the development of children under one year of age born to mothers with multiple sclerosis/InterConf.2020/5/10.<https://ojs.ukrlogos.in.ua/index.php/interconf/article/download/2608/248>
4. Ravshanov Otabek Ravshanovich, Djurabekova Aziza Takhirivna. Features of EEG of frontal and temporal lobe epilepsy in children / <https://cyberleninka.ru/article/n/osobennosti-eeg-lobnoy-i-visochnoy-epilepsii-u-detey.2020>
5. Niyozov Shukhrat Tashmirovich, Djurabekova Aziza Takhirivna, Utaganova Gulzhakhon Kholmuminovna. The use of ozonized cerebrolysin in children with encephalomyelitis. <https://cyberleninka.ru/article/n/primenenie-ozonirovannogo-tserebrolizina-u-detey-s-entsefalomi>.