

## Method of disinfection of an Echinococcal Cyst

**Shamsiev Jamshid Azamatovich,  
Shamsiev Azamat Muhitdinovich,  
Babajanov Nurbek Maxsudovich**  
Samarkand State Medical Institute

### ABSTRACT

*In order to increase the aparasiticity of echinococectomy, to reduce the risk of contact spread of embryos within the operating field, we have developed a "Method for antiparasitic treatment of the echinococcal cyst cavity in an uncomplicated variant of the course of the disease" (Patent for the image No. IAP 2010 0420 dated 08/29/2010), which is distinguished by the fact that cyst puncture is performed and aspiration of its contents, followed by the introduction into the cavity of the chitinous membrane of about the same amount of 80-100% glycerin, heated to 70 ° C, with an exposure of 3-4 minutes.*

*Then the liquid is completely aspirated, the fibrous capsule is dissected, very carefully, the echinococcal cyst is completely removed without damaging it. Next, the inner surface of the fibrous capsule is additionally treated with a hot solution of glycerin for 3-4 minutes, then a microscopic examination of the fibrous capsule washing fluid is carried out to detect the presence of echinococcus embryonic elements (protoscolexes and acephalocysts).*

*The intake of wash water and their microscopy takes 1-2 minutes. After microscopic confirmation of the absence of living germinal elements of the parasite in the washing waters of the fibrous capsule, the residual cavity is closed in a closed or semi-closed way, and if non-dead protoscolexes are found, indicating an error in chemical processing, the procedure is repeated using 80-100% glycerin solution heated to 70 ° C for 5 minutes, and only after reliable antiparasitic treatment of the echinococcal cyst, the operation is completed.*

**Keywords:** *aparasitism, echinococectomy, glycerin, fibrous capsule, echinococcal cyst, microscopy, germ elements of echinococcus, protoscolexes, acephalocysts.*

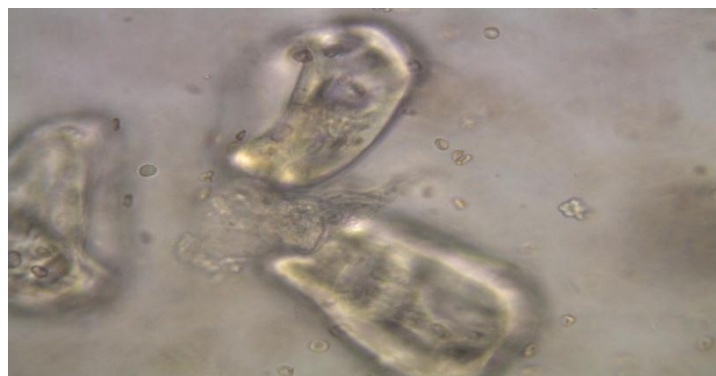
### Introduction

In order to increase the aparasiticity of echinococectomy, to reduce the risk of contact spread of embryos within the operating field, we have developed a "Method for antiparasitic treatment of the echinococcal cyst cavity in an uncomplicated variant of the course of the disease" (Patent for the image No. IAP 2010 0420 dated 08/29/2010), which is distinguished by the fact that cyst puncture is performed and aspiration of its contents, followed by the introduction into the cavity of the chitinous membrane of about the same amount of 80-100% glycerin, heated to 70 ° C, with an exposure of 3-4 minutes.

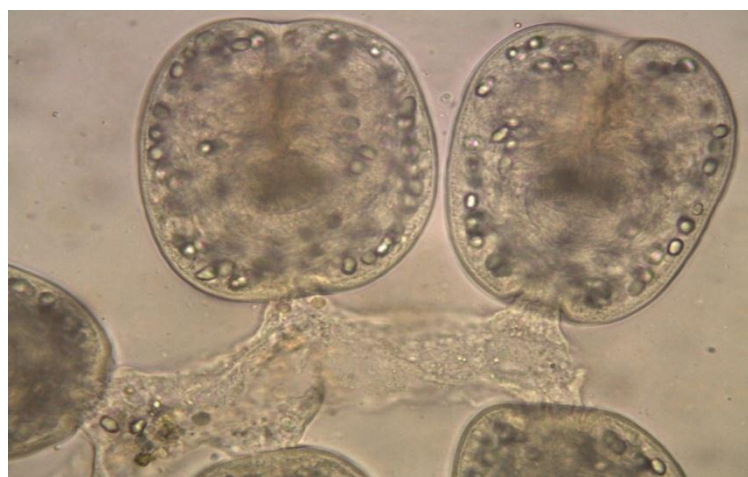
### Main Part

Then the liquid is completely aspirated, the fibrous capsule is dissected, very carefully, the echinococcal cyst is completely removed without damaging it. Next, the inner surface of the fibrous capsule is additionally treated with a hot solution of glycerin for 3-4 minutes, then a microscopic examination of the fibrous capsule lavage fluid is carried out to detect the presence of echinococcus embryonic elements (protoscolexes and acephalocysts). The intake of wash water and their microscopy takes 1-2 minutes.

After microscopic confirmation of the absence of living germinal elements of the parasite in the flushing waters of the fibrous capsule (Fig. 1).



**Fig. 1. Protoscolexes in rinsing waters after exposure to hot glycerin. Magnification x1000.**



**Fig. 2. Living protoscolexes. Magnification x1000.**

The residual cavity is sutured in a closed or semi-closed way, and if non-dead protoscolexes are found (Fig. 2), indicating errors in chemical processing, the procedure is repeated using 80-100% glycerin solution, heated to 70 ° C for 5 minutes, and only after reliable antiparasitic treatment of the echinococcal cyst, the operation is completed. The method of intraoperative disinfection of an echinococcal cyst in a complicated course (Patent for invention No. IAP 04984. Priority 20.12.2011) was slightly modified by us taking into account the bacterial infection of the parasite bed.

The method differs in that the echinococcal cyst is punctured with a thick needle connected to an electric suction device, the parasitic fluid is aspirated, the same amount of 80-100% glycerin heated to 70 ° C is injected into the cavity and kept for 5 minutes, the fibrous capsule is dissected, removed the contents of the echinococcal cyst (chitinous membrane, multiple daughter bubbles, protoscolexes, dead bubbles, purulent detritus and other embryonic elements), the inner side of the fibrous capsule is thoroughly cleaned with gauze tampons, then 80-100% glycerin heated to 70 is poured into the residual cavity of the fibrous capsule ° C, and cavitation is carried out with low-frequency ultrasound with an oscillation frequency of 26.4-26.6 kHz, with a waveguide oscillation amplitude of 75-85 microns for 5 minutes.

After that, the fluid is removed from the fibrous capsule, the effectiveness of the antiparasitic treatment of the contents of the fibrous capsule is checked by microscopic examination, and with the complete death of the germ elements of the parasite, the residual cavity of the fibrous capsule is once again treated with antiseptic solutions (Dimexide, 2% formalin solution, ethanol) and sutured in a closed or semi-closed way.

## Conclusion

In complicated echinococcosis, the indication for the use of ultrasonic cavitation of the fibrous capsule is rather the proven bactericidal properties of low-frequency ultrasound [Teplyakov E.Yu. 2005],

than its scolexicidal qualities, since we indicated above that ultrasonic nanoparticles when treated with hot glycerin do not particularly enhance the germicidal properties of manipulation. In addition, technical difficulties in the application of ultrasonic cavitation may arise when it is impossible to fill the cavity with liquid, in cases of difficult access to the cyst. In such situations, a good help in reliable processing of the fibrous capsule is the proven bactericidal and scolexicidal properties of 80-100% glycerin, the effect of which is enhanced by heating it to 70 ° C.

## References

- 1.Ahmadi N.A., Bodi F. Clinical Presentation, Localization and Morphology of Hepato-Pulmonary Hydatid Cysts in Patients Operated in Tehran. World Applied Sciences Journal 12 (9): 1544-1548, 2011.
- 2.Babuci Stanislav Argumentarea patogenetică și clinico-morfologică a tratamentului medico-chirurgical în hidatidoza pulmonară la copil.:Autoreferat al tezei de doctor habilitat în medicină. CHIȘINĂU 2005. 23 p.
- 3.Jamshed Shamsiev [The experience of using glycerine during the processing of larval cyst cavity](#) Medical Health and Science Journal. 2010. 4. 4. p. 54-59.
- 4.Shamsiyev A.M., Shamsiyev J.A., Kurbaniyazov Z.B., Rakhmanov K.E., Davlatov S.S. [Prevention and pharmacotherapy of liver echinococcosis](#) // Science and education issues. 2017/12/4. p. 159.